

Incidence of loose shell syndrome disease of the shrimp *Penaeus monodon* and its impact in the grow-out culture

A. Gopalakrishnan* and Ajay Parida

M.S. Swaminathan Research Foundation, 128, 9th Cross Street, Kanagasabai Nagar, Chidambaram 608 001, India

This article reports the changes in growth, production and histology of *Penaeus monodon* infested with loose shell syndrome in modified extensive grow-out ponds. The carapace of the affected shrimp is papery in nature and the gill is brown in colour. The gill filament shows fouling by protozoa and muddy particles. Hepatopancreas tissue reveals the absence of fat globules in its cells. Secondary infection of shrimp is caused by microbes and this fouling leads to the severity of the disease. In the loose shell-affected pond, the final average body weight of shrimps on 147 days of culture is 27.87 g, but in the case of the normal pond it is 31.29 g on the 140th day. The average daily growth rate of the loose shell-affected shrimp is 0.18 g and in the normal pond it is 0.22 g. The mean final survival rate of the loose shell-affected pond is 60.65% and in the normal pond it is 81.95%. The mean biomass production of the affected pond is 1058.97 kg/ha⁻¹, and in the normal pond it is 1915.21 kg ha⁻¹. The poor survival and biomass production in the loose shell-affected pond is due to cannibalistic behaviour of the shrimp during loose shell disease. There is also a derangement of parameters, especially salinity and temperature in the loose shell-affected pond.

THE loose shell syndrome is an economically significant disease of *Penaeus monodon* culture in India. The affected shrimp has a paper-like carapace with a gap between the muscle tissue and carapaces¹. The soft shell syndrome is the result of nutritional deficiency, exposure to chemical pesticides, poor pond soil and water conditions, and is highly correlated with poor management practices in the pond². The affected shrimp loses weight during culture and turns into a soft leathery shell. Drastic reduction of daily growth rate during the middle of culture is one of the signs of the disease. Further, secondary infections by fungi, bacteria and protozoa affect the shrimp. In such cases, deposition of muddy particles in the carapace and appendages makes the condition more severe. Loose shell disease affects all size groups, particularly the bigger pond-reared *P. monodon*. However, the impact of this disease on histopathology, growth and biomass production is not properly known. Hence the need for the present study.

Materials and methods

Data were collected from March to August 2003 in ten ponds. The densities of all the ponds are the same (8 m⁻²). The ponds are situated on the northern bank of the Vellar estuary and 7 km west from the mouth region of the estuary in the southeast coast of India (lat 11°26"; long 79°46") (Figure 1). Five of these ponds were loose shell-affected and five were normal ponds. Each pond area (water-spread area) was different and it ranged between 0.48 ha and 0.93 ha. The cultured species was *P. monodon* fed with commercial pellets like starter, grower and finisher, during the culture. Environmental variables such as salinity (hand refractometer), pH (pH pen), dissolved oxygen (Winglers' method) and temperature (°C thermometer) were studied on a weekly basis during the day hours, except the dissolved oxygen, which was measured during early hours of the day. PCR-tested (White spot syndrome virus negative) post-larval (PL-20) seeds were stocked in all the ponds with a density of 8 m⁻². Sampling was done to analyse growth and disease conditions of the shrimp

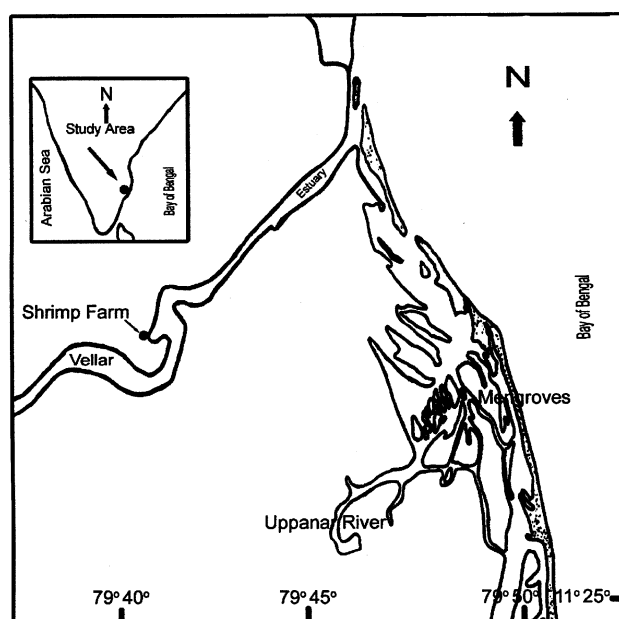


Figure 1. Map showing study area of Vellar estuary.

*For correspondence. (e-mail: ag_krishnan@yahoo.com)

from 28th DOC (day of culture) onwards, once a week, using a cast-net. The shrimps were counted and weighed to determine the weight gain for adjusting the feed ratio. Culture period in the loose shell-affected pond was 147 days and in the normal pond it was 140 days. During weekly sampling, the growth, average body weight, gut fullness and standing biomass of the pond were calculated to optimize the feeding. The final biomass was calculated from the harvest data. For histopathological studies, the diseased shrimp tissues (hepatopancreas, intestine and gill) were fixed in Davidson fixative for 24 h and then transferred to 70% alcohol for further processing. The fixed samples were sectioned at 4 μm thickness and stained with hematoxylin and Eosin. The sections were examined and photographed using photomicrograph (Optiphot-2 Nikon-HFX-DX).

Results

Loose shell disease

After experiencing stresses like bloom crash, water quality and weather changes, the aged ponds with high density during summer are prone to loose shell infection. Protozoa like *Zoothamnium* sp. foul the appendages. In severe cases, the barnacles foul the carapace. The shrimp does not moult for a long time. The gill, pleopod, periopod and other appendages acquire severe fouling in badly affected shrimps and they are brown, black or rusty in colour. Fuzzy mat is evident due to fouling by protozoan on shell and gill of loose-shelled shrimps. This is due to the poor bottom conditions of the ponds. The affected shrimp has a paper-like carapace with a gap between the muscle tissue and exoskeleton (Figure 2). Generally, the gills are reddish to brown in colour (Figure 3 a). Sometimes, the loose shell-diseased shrimps are sky-blue in colour instead of the normal brown-black (Figure 3 b). The indicator of onset of the disease can be predicted by

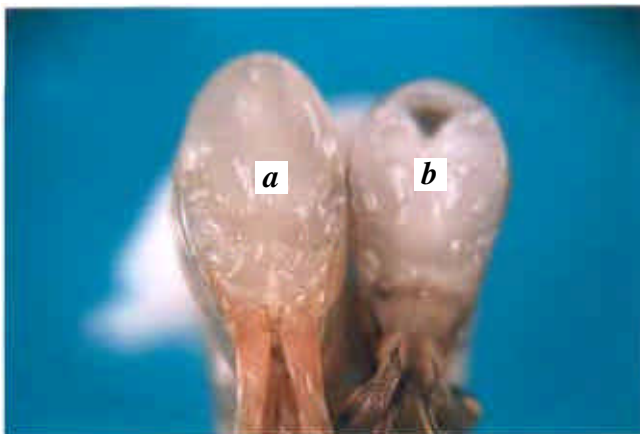

Figure 2. *Penaeus monodon* cut across the tail. **a**, Normal *P. monodon* cross-section of intact muscle. There is no space between muscle tissue and exoskeleton. **b**, Cross-section of loose shell syndrome-affected *P. monodon* with a gap between muscle tissue and exoskeleton.

proper sampling at regular and frequent intervals. One of the first indicators of the disease is an abrupt decline in feed consumption. The probability of onset of the disease can be assessed by an examination of the shrimps at the centre of the pond, shrimps with empty gut or lack of faecal strands in the lift net. Apart from the loose shell condition, the shrimp intestine turns into an opaque milky white colour during severe condition of the disease (Figure 4). Auto-entrants like *Metapenaeus brevicornis* and *Acetes indicus* are also turned into milky white intestine. Deposition of muddy particles on the shrimp surface leads to difficulties during locomotion. Also, during this time, the cannibalistic behaviour of the shrimp is evident in the pond.

Histopathology

Darkening of gill filament due to secondary infection is seen in the gill tissue during histopathological studies. Further, the presence of hemolytic infiltration in the space between the tubules of the gill is evident, and also the melanized non-functional tubules are present in the gill lamellae (Figure 5 a). Fouling of *Zoothamnium* and muddy debris in the gill filament of the shrimp is noticed (Figure 5 b). Sometimes, the gill lamellae show discoloration due to




Figure 3. **a**, Loose shell syndrome-affected *P. monodon* with brown gill. **b**, Loose shell syndrome-affected *P. monodon*.

detritus or silt accumulation and epicommissals (filamentous bacteria, protozoa and algae). In severe cases, it leads to asphyxia. In the gill tissue, the hyperplasia of the gill epithelium is evident.

The hepatopancreas is smaller in size in infected shrimps than healthy ones. Histological examination of the hepatopan-

creas tissue of the affected shrimp shows atrophied tubular cells (Figure 6) and absence of storage vacuoles (Figure 7a) while the normal shrimps show no such changes (Figures 7b). The absence of storage vacuoles is due to continuous starvation of the animal in the pond because of loose shell disease.



Figure 4. Loose shell-affected *P. monodon* with milky white intestine without contents.

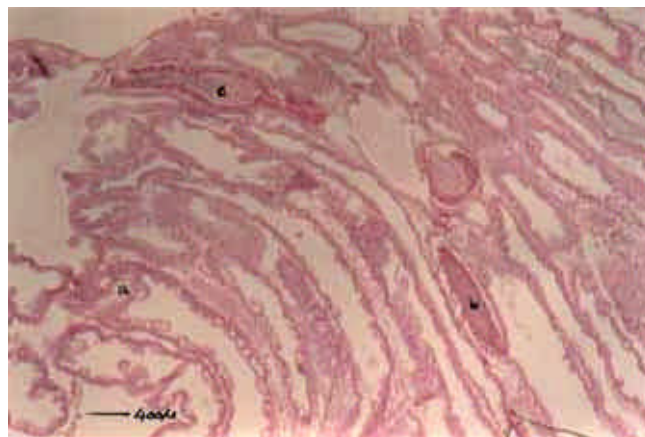


Figure 6. Cross-section of hepatopancreas. (a) Hepatopancreas is atrophied with fibrosis and hemocyte infiltration in the intertubular spaces. (b) Melanzated tubules. (c) Non-functional affected tubules.

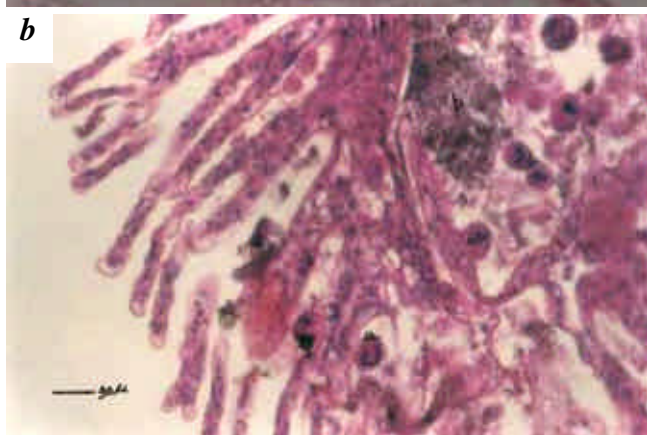
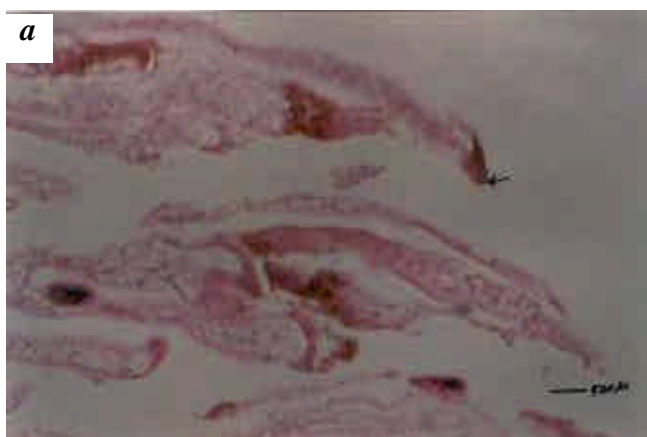

Figure 5. *a*, Darkening of gill filament due to secondary infection. *b*, Cross-section of gill of *P. monodon* (a) Fouling of protozoan (*Zoothamnium* sp.) in the gill filament. *b*, Muddy debris fouling in gill filaments.

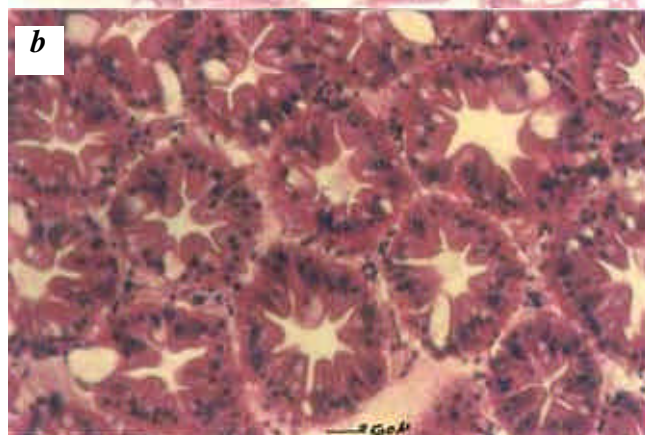
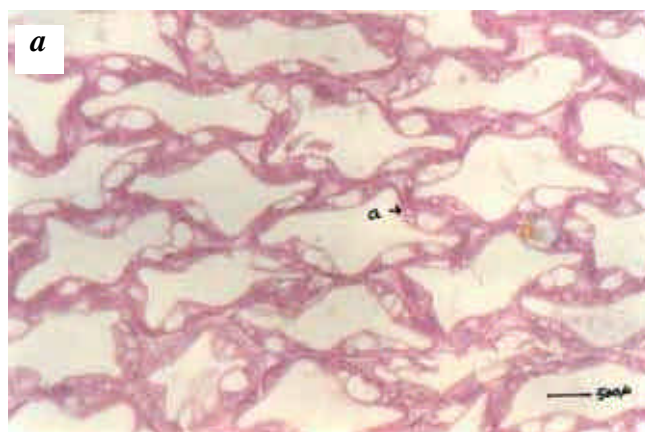
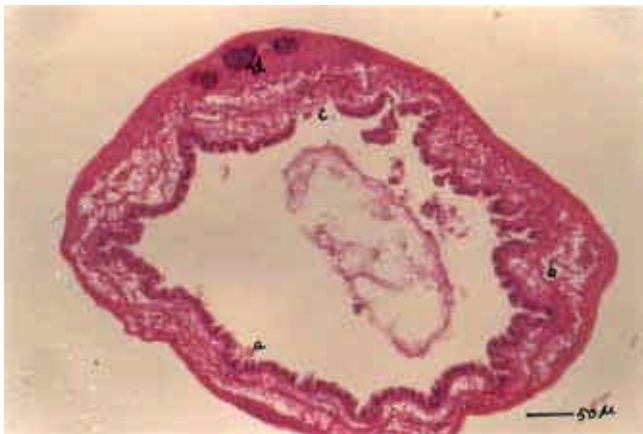

Figure 7. *a*, Hepatopancreas of loose shell syndrome-affected *P. monodon*. (a) Presence of poorly vacuolated cells lining the tubules; *b*, Normal structure of hepatopancreas of healthy *P. monodon* showing well-vacuolated cells.

Table 1. Mean values of grow-out pond shrimp production in both loose shell-affected and normal ponds

Parameter	Normal pond	Loose shell-affected pond
FCR	1.69 (\pm 0.13)	1.95 (\pm 0.13)
Percentage of soft population during harvest	4.86 (\pm 0.91)	8.99 (\pm 1.32)
Survival (harvest)	81.96 (\pm 3.7)	60.67 (\pm 4.36)
Final average body weight	31.29 (\pm 1.38)	27.87 (\pm 2.84)
Total DOC	140	147
Average daily growth rate	0.22	0.18
Biomass/tons ha ⁻¹	1.9 \pm 1.7	1.06 \pm 1.9

**Figure 8.** Cross-section of loose shell diseased *P. monodon* intestine. (a) Necrosis in the intestinal wall. (b) Degeneration of basement membrane. (c) Degeneration of epithelial cell in the inner wall of the intestine. (d) Intra nuclear inclusion bodies.

Intestinal cell necrosis and degeneration of basement membrane are also noticed in the affected shrimp. Further, degeneration of epithelial cells in the inner wall of the intestine and cell necrosis are noticed (Figure 8).

Environmental variables in normal and loose shell diseased ponds

The salinity of the normal pond ranges between 30.6 and 46‰. The temperature of normal pond varies between 28.9 and 32.7°C. Water pH in the pond ranges between 7.6 and 8.6. Soil pH varies from a minimum of 4.62 to a maximum of 6.8. Dissolved oxygen ranges between 5 and 7.34 ppm (Figure 9 a).

Water quality parameters in loose shell-affected ponds are more or less similar. The salinity of the loose shell-affected pond varies between 30.4 and 44‰. pH of the pond water is between 7.6 and 8.6. The soil pH is ranged between 4.62 and 6.49. Dissolved oxygen content of the pond varies between 5.12 ppm on 140th DOC and 2.7 ppm on 133rd DOC. The temperature of the pond does not vary much; it ranges only from 30.2 to 32.5°C (Figure 9 b).

Feeding

The daily feed consumption rate (FCR) is one of the indicators of disease onset in the pond. In the normal pond, the FCR is normal (Figure 10 a). In the loose shell-affected pond, the FCR is reduced substantially (Figure 10 b).

Growth and production

In the present investigation, the FCR in the loose shell syndrome-affected pond is between 1.82 and 2.08. This is an abnormal level for shrimp culture. In the normal pond, the FCR ranges between 1.56 and 1.82. Shrimp biomass production in the loose shell-affected pond ranges between 0.758 and 1.338 tons ha⁻¹. In the case of normal pond, it ranges from 1.797 to 2.086 tons ha⁻¹. The average body weight of the shrimp during harvest in the loose shell syndrome-affected pond is between 25.98 and 31.32 g and in the normal pond it is between 29.44 and 32.12 g (Figure 11 a and b). The total DOC for the normal pond is 140, and for the loose-shell syndrome-affected pond it is 147. The daily growth rate of the shrimp pond is important for efficient FCR. In the present study, the loose shell-affected shrimp shows minimum mean daily growth rate (DGR) value of 0.02 g on 105th DOC and maximum value of 0.40 g on 63rd DOC. In the normal pond, maximum DGR of 0.371 g has been achieved on 77th DOC and minimum of 0.24 g on 105th DOC (Figure 11 a). It is evident that shrimp survival in the normal and loose shell-affected ponds varies greatly. In the normal pond, the mean final survival is 81.95% and in the case of loose shell-affected pond it is only 60.68% (Figure 12). During harvest, the mean soft shell in the loose shell-affected pond is 8.99% and it is 4.86% in the normal pond.

Discussion

Loose shell disease is one of the non-infectious shrimp diseases, which causes serious threat to shrimp industry³. The loose shell syndrome is the result of chronic toxic pond-bottom conditions due to the release of ammonia and nitrates⁴. The shrimps apparently suffocate when dense colonies of foulers reduce the effective respiration surface

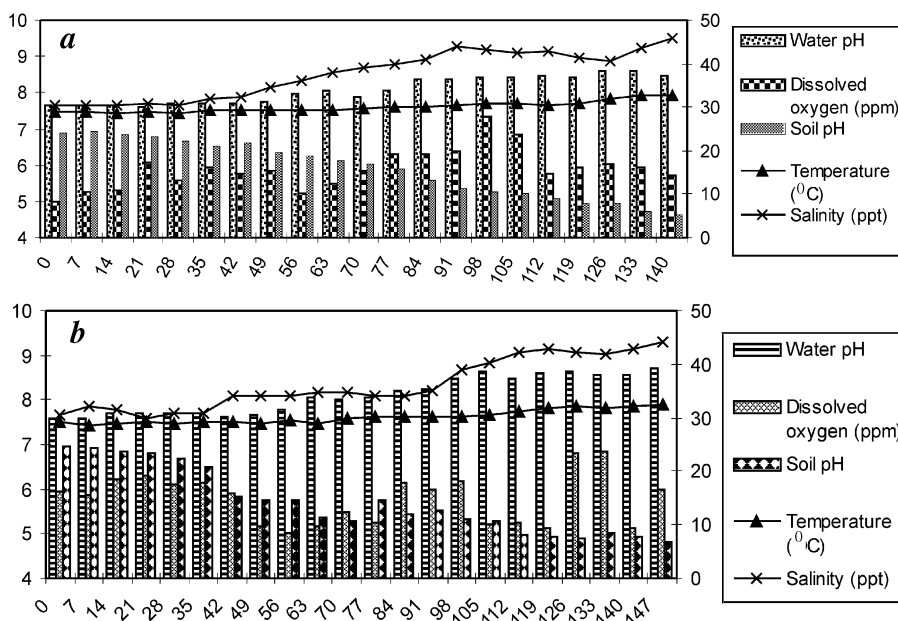


Figure 9. Water quality parameter in (a) normal pond and (b) loose shell diseased pond.

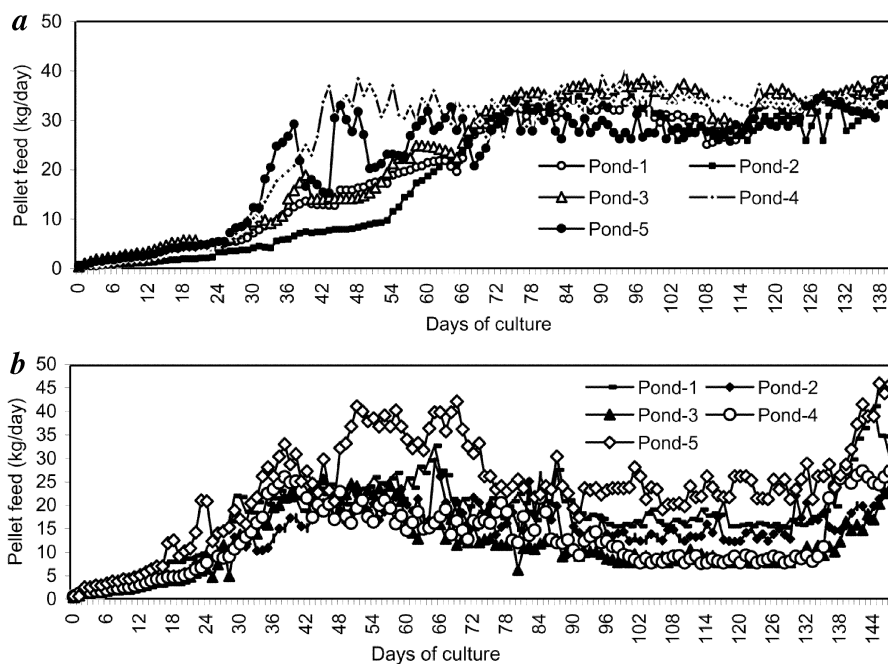


Figure 10. Daily pellet feed consumption in (a) normal ponds (b) loose shell diseased ponds.

area of the gill⁵. Good water quality is an important preventive measure⁶.

Chronic cases of long-term pollution and zoothamnium fouling of the shell and gill of *P. monodon* lead to shrunken hepatopancreas⁷. The main function of the hepatopancreatic R-cell is storage of food⁸. The poor vacuolation of hepatopancreas in soft-shelled shrimps is reportedly due to chronic

starvation of the shrimps⁹. The hepatopancreatic tubules of loose-shelled shrimps are mostly disarranged and disrupted. In the loose-shelled shrimp, compressed hepatopancreatic tubules are found. Poor consumption of pellet feed leads to cannibalism of shrimps in the pond¹⁰. The dissolved oxygen levels should be kept above 2 ppm at all times¹¹. In the present study, the minimum dissolved oxygen is above 5 ppm

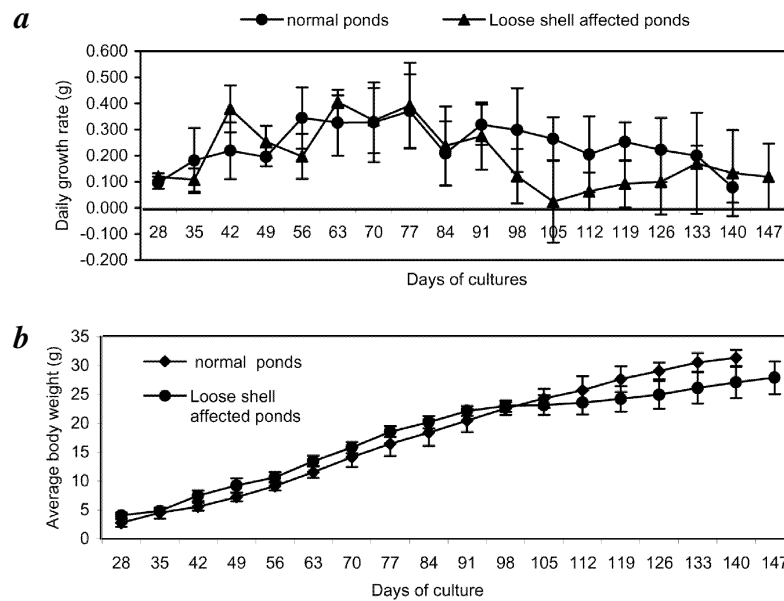


Figure 11. *a*, Daily growth rate of *P. monodon* in normal and loose shell-affected pond. *b*, Growth of *P. monodon* in normal and loose shell affected ponds.

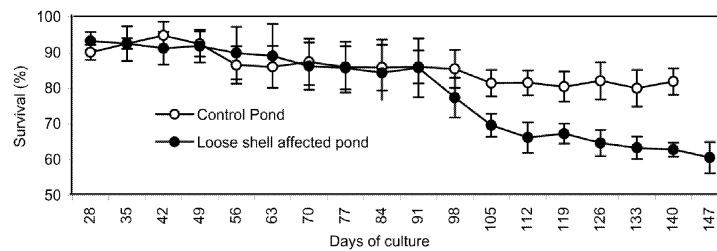


Figure 12. Mean survival of *P. monodon* in normal and loose shell-diseased ponds.

in both the ponds. The ponds have been installed with paddle wheel aerators. Earlier workers have observed the shrimp mortalities in the pond when the oxygen level reaches as low as 2.7 ppm during the night hours¹².

Temperature plays a vital role in the metabolism of shrimps. In grow-out ponds, the temperature should range from 25 to 30°C; values greater than this range are lethal to shrimps¹³. During the present study the temperature ranged between¹⁴ 28.7 and 32.7°C. The ideal salinity for *P. monodon* is 15–25 ppt, and high or low salinity beyond the optimal range affects the normal physiology of shrimps¹⁵. In this study, it ranges between 30.4 and 46 ppt. The feed consumption pattern in normal and loose shell-affected ponds differs. There is a sudden fall in daily consumption of pellet feed in the loose shell disease-affected pond. In the normal pond, pellet feed consumption is normal. The feeding response may be reduced by 30–50% at temperatures¹⁶ higher than 32–33°C. The average daily growth rate of shrimp in the loose shell-affected pond is 0.18 g and in the normal pond it is 0.22 g. Maximum daily growth rate of 0.17 g for

P. monodon culture pond has been recorded earlier¹⁷. Compared to the normal pond, in the present study the loose shell-affected pond has recorded poor daily growth rate, which ultimately leads to prolonged culture days to reach the harvestable size. The mean survival rate in the loose shell-affected pond is 60.68% and in the normal pond it is 81.95%. The poor survival in the loose shell-affected pond is due to cannibalistic behaviour of shrimps in the pond. The final survival of *P. monodon* has previously been reported¹⁸ to be 81.7% at the stocking density of 11 m⁻². The density of 5–20 prawns m⁻² has shown no effect on the survival rate¹⁹. Comparable results have been reported at a stocking rate of 5 m⁻² and at 7.5 m⁻² on growth and survival of pond-reared *P. monodon*²⁰.

Earlier work has recorded a production of 800–2500 kg ha⁻¹ per crop for a system of shrimp culture, where feed inputs are a major source of nutrients for shrimp in ponds²¹. Production of 700 kg ha⁻¹ to 11.2 tons ha⁻¹ has been reported in Taiwan²². In the present study, production in the normal pond is 1.797 to 2.086 tons ha⁻¹, and in the loose shell-affected pond it

RESEARCH ARTICLES

ranges between 0.75 and 1.338 tons ha⁻¹. A previous study has recorded about 3% soft-shelled shrimps at 20 m⁻² density culture²³, whereas the present study has observed 8.99% of diseased shrimps (soft-shelled) at 8 m⁻² density.

1. MPEDA/NACA, *Shrimp Health Management Extension Manual*, MPEDA, Cochin, 2003.
2. Baticados, M. C. L., Coloso, R. M. and Duremdex, R. C., Histopathology of the chronic soft-shell syndrome in the tiger prawn, *P. monodon*. *Dis. Aquat. Org.*, 1986, **3**, 13–28.
3. Lightner, D. V. and Kumulu, M., Disease of penaeid shrimp. In *CRC Hand Book of Mariculture: Crustacean Aquaculture* (ed. McVey, J. P.), CRC Press, Boca Raton, FL, 1993, 2nd edn, pp. 393–486.
4. Baticados, M. C. L., Curz-Lacierda, E. R., de la Cruz, M. C., Duremdex-Fernandez, R. C., Gacutan, R. Q., Lavilla-Pitogo, C. R. and Lio-Po, G. D., *Diseases of Penaeid Shrimp in the Philippines*, Aquaculture Extension Manual No. 16. Aquaculture Department, Southeast Asian Fisheries Development Centre, Philippines, 1990, p. 46.
5. Lightner, D. V., Some potentially serious problems in the culture of penaeid shrimp in North America. Proc. US–Japan Natural Resource Programme, Symposium on Aquaculture Diseases, Tokyo, 1975, pp. 75–97.
6. Rutledge, W. P. and Guest, W. C., Marine finfish culture in Texas. *Aquaculture*, 1977, **12**, 137–140.
7. Nash, G., *Penaeus monodon* grow-out diseases. In *Technical and Economic Aspects of Shrimp Farming*, Proceeding of the Aquatech 1990 Conference, Kuala Lumpur, Malaysia (eds New, M. B., de Saram, H. and Singh, T.), INFOFISH and Fisheries Development Authority of Malaysia, 11–14 June 1990, pp. 172–190.
8. Storch, V., Janssen, H. H. and Cases, E., The effect of starvation of the hepatopancreas of Cocony Crab, *Birgus latro* (L.) (Crustacea, Decapoda). *Zool. Anz.*, 1982, **208**, 115–123.
9. Vogt, G., Histologie und cytologie der Mitteld-driise von *Penaeus monodon* (Decapoda). *Zool. Anz.*, 1985, **215**, 61–80.
10. Soyil, H. L. and Kumlu, M., *Turk. J. Zool.*, 2003, **27**, 221–225.
11. Law, A. T., Water quality requirements for *Penaeus monodon* culture. In Proceedings of the Seminar on Marine Prawn Farming in Malaysia Serdang, Malaysia Fisheries Society, Malaysia, pp. 53–65.
12. Shigueno, K., Shrimp culture in Japan. Assoc. for International Technical Promotion, Tokyo, Japan, 1975, p. 153.
13. Boyd, C. E. and Fast, A. W., Pond monitoring and management. *Marine Shrimp Culture: Principle and Practices*, Elsevier, 1992, pp. 497–513.
14. Johson, S. K. and Cassout, D., Tara virus hits Texas. *World Aquacult.*, 1995, **26**, 37.
15. Chamretchakool, P., Turnbull, J. F., Funge Smith, S. I., Mac Rac, F. H. and Limsuwan, C., In *Health Management in Shrimp Ponds*, Aquatic Animal Health Research Institute, Kesetsart Unazy Capeas, Taiwan, 1998, 3rd edn, p. 152.
16. Boyd, C. E., Water quality management and aeration in shrimp farming. Fisheries and Allied Aquaculture Department Series, An-buru University, 1989, 2: 83.
17. Santiago, Jr. A. C., Successful spawning of cultured *Penaeus monodon*. (Fabricius) after eyestalk ablation. *Aquaculture*, 1977, **11**, 185–196.
18. Wyban, J. A., Lec, C. S., Sato, V. T., Seveaney, J. N. and Richards, Jr. W. K., Effects of stocking on shrimp growth rates in manure fertilized ponds. *Aquaculture*, 1987, **61**, 23–32.
19. Trino, A. and Sarroza, J., Effect of a diet lacking in vitamin and mineral supplements on growth and survival of *Penaeus monodon* juveniles in a modified extensive culture system. *Aquaculture*, 1995, **136**, 323–330.
20. Akiyama, D. M. and Chwang, N. L. M., Shrimp feed requirements and feed management, In Proceedings of the Southeast Asia Shrimp Farm Management Workshop (ed. Akiyama, D. M.), 26 July–11 August, American Soybean Association, Republic of Singapore, 1989.
21. Liaco, I. C. and Chao, N. H., Development of prawn culture and its related studies in Taiwan. In Proceeding of the International Warm Water Aquaculture Conference (eds Rogers, G. L., Day, R. and Lim, A.), Bringham Young University, Hawaii Campus, 1983.
22. Millamena, O. M. and Trino, A. T., Low-cost feed for *Penaeus monodon* reared in tanks and under semi-intensive and intensive conditions in brackishwater ponds. *Aquaculture*, 1997, **154**, 69–78.
23. Allan, G. L. and Maguire, G. B., Effect of pH and salinity on survival, growth and osmoregulation in *Penaeus monodon* (Fabricius). *Aquaculture*, 1992, **104**, 33–47.

ACKNOWLEDGEMENTS. We thank Prof. M. S. Swaminathan, Chairman, Prof. M. Veylayutham, Executive Director and Dr K. Balasubramanian, Director JRD Tata Ecotechnology Centre, M.S. Swaminathan Research Foundation, Chennai. We also thank Prof. K. Kathiresan, CAS in Marine Biology, Annamalai University, constructive comments. We are grateful to the farmers of Vellar estuary.

Received 29 June 2004; revised accepted 25 February 2005